M. Halberstadt[1]
D. Domig[1]
L. Kodjikian[2]
F. Koerner[1]
J. G. Garweg[3]

PVR Recurrence and the Timing of Silicone Oil Removal

Zeitpunkt zur Ölentfernung bei erneuter PVR-Bildung unter Öl

Zusammenfassung

Hintergrund: Nach Vitrektomie findet sich oft bei unter Öl stabil anliegender Netzhaut eine PVR-Progression. Aufgrund der dadurch erhöhten Gefahr einer PVR-Re-Amotio nach Ölentfernung ist der Zeitpunkt zur Ölentfernung kritisch. Bei späterer Entfernung der Tamponade kann möglicherweise die PVR-Bildung zur Ruhe kommen, die PVR komplett entfernt und die Gefahr einer PVR-Re-Amotio nach Ölentfernung gesenkt werden. Ziel dieser Studie war es daher zu ermitteln, ob eine verlängerte Verweildauer der Tamponade das anatomische Resultat verbessern kann, ohne den funktionellen Erfolg zu beeinträchtigen. **Patienten und Methoden:** Für die vorliegende retrospektive Analyse wurden die Krankengeschichten von 112 konsekutiven Patienten ausgewertet, bei denen wegen rhegmatogener und PVR-Amotio retinae eine Vitrektomie mit Ölfüllung durchgeführt worden war. In allen Fällen konnte unter Öl die Netzhaut zur Anlage gebracht werden. Nach Entfernung der Öltamponade musste der postoperative Verlauf mindestens 6 Monate betragen. Die Patienten wurden entsprechend der Dauer bis zur Ölentfernung in 3 Gruppen eingeteilt. Bei ausbleibender Re-PVR wurde das Öl binnen 4 – 12 Monaten entfernt (Gruppe 1: n = 43). Fälle mit Re-PVR unter Öl wurden gemäß der Verweildauer der Tamponade in 2 Gruppen eingeteilt: 12 – 18 Monate (Gruppe 2: n = 48); > 18 Monate (Gruppe 3: n = 21). Als primäre Erfolgsparameter wurden sechs Monate nach Ölentfernung der anatomische Erfolg, der intraokulare Druck und die bestkorrigierte Sehschärfe erfasst. **Ergebnisse:** Sechs Monate nach Entfernung der Öltamponade unterschieden sich die drei Gruppen hinsichtlich des anatomischen Erfolgs (84,6 %, 86,3 %, 88,8 % log rank = 0,794), des

Abstract

Background: Following vitrectomy for PVR-associated retinal detachment, placement of an encircling band, filling with silicone oil (SO) and successful retinal reattachment, a recurrence of PVR can develop. Retinal redetachment after SO removal is usually due to secondary or residual PVR. We wanted to ascertain whether the anatomical and functional outcomes of surgery in patients with a reattached retina and recurrent PVR can be improved by delaying the removal of SO. **Patients and Methods:** 112 consecutive patients with PVR-associated retinal detachment who had undergone vitrectomy with SO filling, were monitored for at least 6 months after SO removal. Prior to SO removal, the retina posterior to the encircling band had to be completely reattached. Patients who developed PVR after SO filling were divided into two groups according to the duration of SO retention: 12 – 18 months (group 2: n = 48); > 18 months (group 3: n = 21). Individuals without PVR recurrence after SO filling and in whom the SO was consequently removed within 4 – 12 months served as control (group 1: n = 43). Anatomical success, intraocular pressure (IOP) and best-corrected visual acuity (BCVA) served as the primary clinical outcome parameters. **Results:** Six months after SO removal, the anatomical success rates (86.3 %, 88.8 % and 84.6 %, in groups 1, 2 and 3, respectively; log rank = 0.794) and the BCVAs (p = 0.861) were comparable in the three groups. Mean IOP (p = 0.766), and the frequency of complications such as PVR recurrence (p = 0.936), bullous keratopathy (p = 0.981) and macular pucker (p = 0.943) were likewise similar. Patients in whom SO was retained for more than 18 months had the highest IOPs and required the heaviest dosaging with anti-glaucoma

Institutsangaben
[1] Department of Ophthalmology (Chairman: Prof. Dr. Dr. S. Wolf), University of Bern, Inselspital, Bern, Switzerland
[2] Croix-Rousse Hospital, Service d'ophtalmologie (Chairman: Prof. Dr. Jean-Daniel Grange), Lyon, France
[3] Swiss Eye Institute (Chairman: Prof. Dr. J. G. Garweg), Gossetstr. 43; 3084 Wabern, Switzerland

Korrespondenzadresse
Markus Halberstadt, MD · Department of Ophthalmology, Inselspital · 3010 Bern · Switzerland · Tel.: ++ 41/31/6322501 · Fax: ++ 41/31/3824779 · E-mail: markus.halberstadt@insel.ch

Eingegangen: 17.9.2005 · **Angenommen:** 31.1.2006

Bibliografie
Klin Monatsbl Augenheilkd 2006; 223: 361 – 366 © Georg Thieme Verlag KG Stuttgart · New York
DOI 10.1055/s-2006-926594
ISSN 0023-2165

intraokularen Druckes (p = 0,766) und der bestkorrigierten Sehschärfe (p = 0,861) nicht. Nach Ölentfernung traten in den drei Gruppen Komplikationen wie erneute PVR (p = 0,936), bullöse Keratopathie (p = 0,981) oder epimakuläre Fibroplasie (p = 0,943) in vergleichbarer Häufigkeit auf. Allerdings wurden in Gruppe 3 höhere intraokulare Druckwerte und eine höhere Anzahl antiglaukomatöser Medikamente dokumentiert. **Schlussfolgerungen:** Bei unter Silikonöl stabil anliegender Netzhaut, aber erneuter PVR-Bildung kann das Öl bis zu 18 Monate belassen werden, um weitere morphologische Veränderungen erfassen und gegebenenfalls darauf reagieren zu können. Eine längere Verweildauer erhöht das Risiko für die Entwicklung eines Sekundärglaukoms, ohne die anatomische Erfolgsrate zu erhöhen.

Schlüsselwörter
Vitrektomie · Silikonöl · PVR · Netzhautablösung

drugs. **Conclusions:** In patients who develop a recurrence of PVR after vitrectomy and SO filling the surgeon can observe and treat retinal changes for up to 18 months without impairing the anatomical and functional outcomes. The retention of SO for more than 18 months does not improve the anatomical outcome. However, it can impair the functional outcome by precipitating the development of a persisting secondary glaucoma.

Key words
Outcome assessment · PVR · retinal detachment · silicone oil · vitrectomy

Introduction

Since the long-term use of a tamponade of silicone oil (SO) is associated with complications [6, 8], it is generally recommended to remove it as soon as the retina is deemed to be stably reattached [6, 10]. Currently recommended times for the removal of SO after surgical reattachment vary from 3, through 6 [7], to 22 months [13]. The most common complication following SO removal is retinal redetachment, which occurs at an estimated frequency of 9 – 33 % [3, 7, 13, 30], and is usually due to secondary or residual PVR [16]. The chance of completely and permanently removing the PVR may be enhanced after its maturation. Furthermore, a complete and permanent removal of PVR may reduce the risk of retinal redetachment. The classification of PVR as active or mature often depends merely on the development of morphological findings during the follow-up course [21, 22].The chances of PVR becoming inactive appear to increase in proportion to the time that an SO tamponade remains in place. Hence, when retinal reattachment is achieved by surgery but followed by a postoperative recurrence of PVR there may be a tendency to delay SO removal [20] or to perform prophylactic retinal laser photocoagulation [1, 20, 29]. However, it is not known whether the final anatomical outcome can be really improved by delaying SO removal. Clinically, such a strategy would be applied if the functional outcome is not impaired. Hence, the aim of the present study was to ascertain whether a delay in the removal of SO can improve the anatomical result without impairing the functional outcome in vitrectomized patients with PVR recurrence.

Patients and Methods

112 consecutive patients were included in this retrospective study. Each individual had undergone vitrectomy, which was combined with the placement of an encircling band (2.0-mm silicone band) and primary filling with SO (5000 CSi) for PVR-associated retinal detachment (stage B or higher [31]). In all cases, the filling with SO was the first one in the patient's history. However, due to the complexity of the primary retinal detachment some patients had undergone retinal surgery on former occasions (Table **1**), but without SO filling. Although slit-lamp examination of pseudophakic eyes revealed the posterior capsule to be intact, either slight damage to this structure or to the zonulae could not be excluded. Hence, at the time of SO placement, an inverse iridectomy was routinely performed in pseudophakic eyes to avoid disturbances in the circulation of the aqueous humour and the percolation of SO into the anterior chamber [2]. Surgery was performed between February 1995 and May 2000 in the Department of Ophthalmology at the University of Bern, Switzerland. The study was approved by the Ethics Committee of the University of Bern and was performed in accordance with the ethical standards laid down in the Declaration of Helsinki (1964).

Patients manifesting the following conditions at the time of oil placement were excluded from the study: pre-existing glaucoma that was not sufficiently controlled, diabetic retinopathy, ocular trauma, retinal vascular occlusion, a history of SO filling, aphakia or anterior-chamber lens.

The removal of SO was usually effected by its exchange with balanced salt solution. As required, this step was combined with dissection of the posterior capsule, phacoemulsification and the implantation of an intraocular lens, with membrane peeling, with retinectomy or with endolaser photocoagulation. Following surgery, air or a mixture of air and 15 % SF_6 was introduced into each eye as an internal tamponade (Table **2**). In all cases requiring an additional retinectomy or membrane peeling, a temporary tamponade consisting of air and 15 % SF_6 was introduced. If emulsified SO had entered the anterior chamber this compartment was thoroughly lavaged via a paracenthesis. Unless the intraocular pressure (IOP) rose above 21 mmHg, the latter event was not defined as an SO-associated complication.

All patients undergoing SO removal were scheduled for visits at 1 week, 1 month, 3 months and 6 months postoperatively. The primary outcome parameters were anatomical success and best-corrected visual acuity (BCVA) 6 months after SO removal. However, we also assessed the IOP, the number of anti-glaucomat drugs administered, the frequency of anti-glaucoma surgery (cyclophotocoagulation or trabeculectomy), the recurrence of PVR,

Table **1** Profile before SO removal (n. d. = statistical difference not determined owing to group definition)

factor	*group 1*	*group 2*	*group 3*	*p value*
		time of SO removal		
	(4 – 12 months) n = 43	*(12 – 18 months) n = 48*	*(> 18 months) n = 21*	
age, years (mean ± SD)	56.0 ± 18.9	53.7 ± 17.7	54.2 ± 15.8	0.909[1]
gender (male; n [%])	17 (39.5 %)	28 (58.3 %)	7 (33.3 %)	0.082[2]
BCVA; Snellen decimal (mean ± SD)	0.15 ± 0.1	0.11 ± 0.09	0.11 ± 0.07	0.835[1]
amblyopia (n [%])	6 (14 %)	3 (6.25 %)	1 (4.8 %)	0.322[2]
macular hole (n [%])	1 (2.3 %)	2 (4.2 %)	2 (9.5 %)	0.421[2]
history of macular detachment (n [%])	31 (72.1 %)	38 (79.2 %)	17 (81.0 %)	0.641[2]
IOP, mmHg (mean ± SD)	16.4 ± 5.8	17.9 ± 6.5	18.2 ± 4.2	0.873[1]
number of previous retinal surgeries (mean ± SD)	0.94 ± 0.96	1.01 ± 1.45	1.15 ± 2.15	0.902[1]
pseudophakia (n [%])	26 (60.5 %)	25 (52.1 %)	10 (47.6 %)	0.568[2]
PVR stage [31] prior to SO filling (n [%])				
B	7 (16.3 %)	10 (20.8 %)	3 (14.3 %)	0.670[2]
C1, C2	19 (44.2 %)	18 (37.5 %)	7 (33.3 %)	
C3	10 (23.3 %)	12 (25.0 %)	6 (28.6 %)	
D1 – D3	7 (16.3 %)	8 (16.7 %)	5 (23.8 %)	
recurrence of PVR with SO in place (n [%])	0 (0 %)	48 (100 %)	21 (100 %)	n. d.

[1] one-way ANOVA.
[2] $\chi 2$-test (Pearson).

Table **2** Intraoperative profile in relation to the time of SO removal (n. d. = statistical difference not determined owing to group definition)

factor	*group 1*	*group 2*	*group 3*	*p value*
		time of SO removal		
	(4 – 12 months) n = 43	*(12 – 18 months) n = 48*	*(> 18 months) n = 21*	
air (n [%])	13 (30.2 %)	15 (31.3 %)	5 (23.8 %)	0.815[1]
SF_6/air mixture (n [%])	30 (69.8 %)	33 (68.8 %)	16 (76.2 %)	0.815[1]
membrane peeling (n [%])	0 (0 %)	48 (100 %)	21 (100)	n. d.
retinectomy(n [%])	0 (0 %)	9 (18.8 %)	5 (23.8 %)	0.006[1]
laser coagulations (n [%])	15 (34.9 %)	21 (43.8 %)	11 (47.6 %)	0.390[1]
phacoemulsification and IOL implantation (n [%])	5 (11.6 %)	17 (35.4 %)	9 (42.9 %)	0.009[1]

[1] $\chi 2$-test (Pearson).

and the occurrence of macular pucker or bullous keratopathy. To facilitate a comparison of our findings with existing data [3, 4, 14], anatomical success was defined as complete retinal reattachment posterior to the encircling band, with no recurrence of PVR. At all scheduled visits, the PVR was monitored by a thorough examination of the retina, including an inspection of its periphery with a three-mirror contact lens. PVR was classified according to the criteria defined by the Retina Society Terminology Committee [31]. The recurrence of PVR was documented in case of PVR Stage B or higher. Since epimacular membranes are rarely the cause of retinal redetachment, they were not defined as PVR. The redevelopment of PVR after its complete removal, or an increase in PVR after its partial removal, were defined as recurrences.

Generally, SO was removed after a stable retinal situation had been achieved, with no evidence of postoperative recurrence of PVR within 4 – 12 months (group 1: n = 43). In patients who developed PVR postoperatively, the removal of SO was delayed for 12 – 18 months according to the estimation of retinal changes by the surgeon (group 2: n = 48). The removal of SO was prolonged beyond 18 months and only performed according to the patient's wish, in the absence of SO-associated complications and if a regular monitoring in the future seemed possible (group 3: n = 21). In cases of anterior retinal redetachment or anterior PVR, a focal or 360° laser retinopexy [1, 20, 25, 29] had been applied prior to SO removal.

Statistics

The statistical analysis was performed using SPSS for Windows version 11.5 (Chicago, Illinois, USA). In cases of amblyopia, macular pathology or when the BCVA was less than 0.2 prior to the initial SO filling, BCVA was not considered in the statistical analysis. For statistical purposes, decimal visual acuity was converted into a logMAR equivalent [log of the minimum angle of resolution: logMAR = -log (decimal acuity)]. On this scale, hand motions and the counting of fingers at a distance of 60 cm correspond approximately to visual acuities of 0.001 and 0.01, respectively. The cumulative probability of surgical success 6 months after SO removal was analyzed by using the Kaplan-Mei-

Table **3** Profile 6 months after SO removal

factor	*group 1*	*group 2*	*group 3*	*p value*
		time of SO removal		
	(4–12 months) n = 43	*(12–18 months) n = 48*	*(> 18 months) n = 21*	
BCVA; Snellen decimal (mean ± SD)	0.21 ± 0.17	0.19 ± 0.13	0.17 ± 0.19	0.861[1]
macular pucker (n [%])	3 (7.0 %)	3 (6.3 %)	1 (4.8 %)	0.943[2]
recurrence of PVR after SO removal (n [%])	2 (4.7 %)	3 (6.3 %)	1 (4.8 %)	0.936[2]
bullous keratopathy (n [%])	4 (9.3 %)	4 (8.3 %)	2 (9.5 %)	0.981[2]
Pseudophakia (n [%])	31 (72.1 %)	42 (87.5 %)	19 (90.5 %)	0.087[2]
IOP, mmHg (mean ± SD)	15.3 ± 9.5	15.5 ± 5.2	17.7 ± 3.2	0.766[1]
number of anti-glaucoma drugs (n; mean ± SD)	0.06 ± 0.34	0.37 ± 0.76	0.61 ± 0.82	0.075[1]
number of anti-glaucoma surgeries (n [%])	5 (11.6 %)	2 (4.2 %)	2 (9.5 %)	0.063[2]
time to redetachment, months (mean ± SD)	5.34 ± 9.1	1.12 ± 1.3	1.38 ± 2.3	0.167[1]
retinal reattachment, cumulative probability [%]	86.3	88.8	84.6	0.794[3]

[1] One-way ANOVA.
[2] $\chi 2$-test (Pearson).
[3] Log-rank (Mantel-Haenszel test).

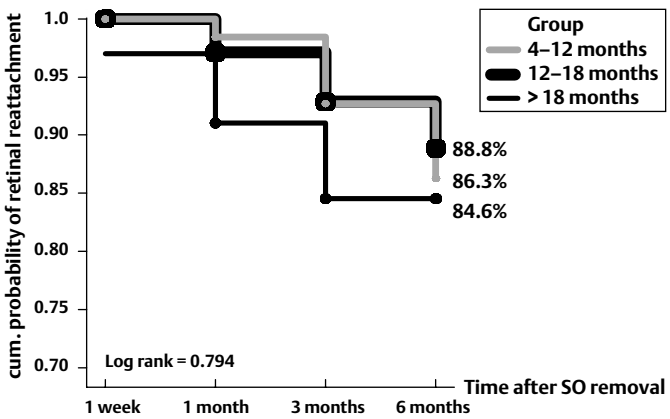

Fig. **1** Cumulative probability of anatomical success 6 months after SO removal.

er survival test. Data were compared using the Mantel-Haenszel test. Between the three groups, qualitative data were compared using chi-square (χ^2)-test and quantitative data using one-way ANOVA. Patients who underwent anti-glaucoma surgery were excluded from the statistical analysis of IOP, and that of the number anti-glaucoma drugs administered. Differences between sets of data were considered to be significant if p values were ≤ 0.05 (on the basis of two-tailed tests).

Results

Demographic and population factors such as age, gender and PVR stage [31] were equally distributed between the groups. There were no significant differences with respect to the frequencies of past vitreoretinal operations, pseudophakia, amblyopia, macular detachment or macular holes (Table **1**). After the removal of SO the percentages of patients with introduced temporary tamponades of either air or an air/SF_6 mixture did not differ between the three groups (p = 0.815; Table **2**). Retinal laser photocoagulation at the time of SO filling or, at latest, a few weeks prior to SO removal, was performed with similar frequencies in the three groups (34.9 %, 43.8 % and 47.6 % in groups 1, 2 and 3, respectively; p = 0.390). In the presence of a visually relevant cataract, SO removal was combined with phacoemulsification and the implantation of an intraocular lens. Consequently, the number of pseudophakic eyes increased with the duration of SO retention. Nevertheless, 6 months after SO removal, the frequency of pseudophakic eyes did not differ between the groups (72.1 %, 87.5 % and 90.5 % in groups 1, 2 and 3, respectively, p = 0.087, Table **3**).

Six months after SO removal, the anatomical success rates were similar in three groups (86.3 %, 88.8 % and 84.6 % in groups 1, 2 and 3, respectively; log rank = 0.794; Table **3** and Fig. **1**). Likewise, the average time elapsing before retinal redetachment did not differ between the three groups (p = 0.167, Table **3**). The frequency of PVR recurrence after SO removal was similar in each group (4.7 %, 6.3 % and 4.8 % in groups 1, 2 and 3, respectively, p = 0.936). Each recurrence of PVR after SO removal led to retinal redetachment. In the remaining patients, an explicit cause of retinal detachment could not be identified (9.8 %, 4.7 % and 10 % in groups 1, 2 and 3, respectively, p = 0.634). Nevertheless, a recurrence of PVR could be excluded.

Six months after SO removal, BCVA (p = 0.861) and IOP (p = 0.766) did not differ significantly between the groups (Table **3**). Changes in the postoperative course of BCVA and IOP after SO removal are depicted in Fig. **2** and Fig. **3**. After SO removal, IOP dropped slightly but not significantly in each group (Fig. **3**). Even so, patients in group 3 were administered the highest number of anti-glaucoma drugs to control IOP (p = 0.075). The percentages of patients requiring anti-glaucoma surgery (p = 0.063), and the frequency of complications such as macular packers (p = 0.943) or bullous keratopathies (p = 0.981) did not differ significantly between the groups (Table **3**).

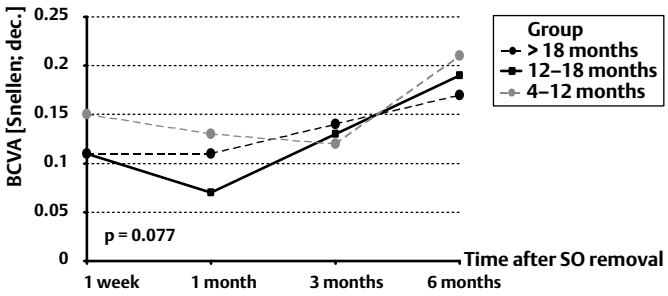

Fig. **2** Course of best-corrected visual acuity (BCVA) after SO removal.

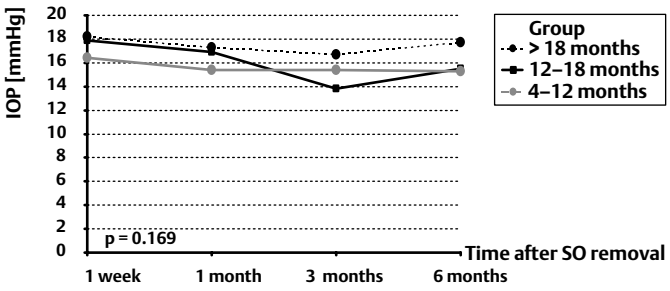

Fig. **3** Course of intraocular pressure (IOP) after SO removal.

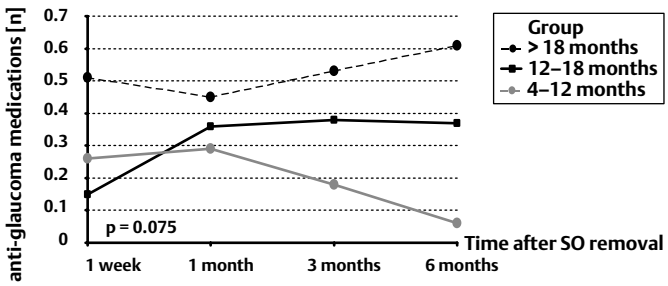

Fig. **4** Number of anti-glaucoma drugs administered.

Discussion

Retinal redetachment is the most common complication associated with the removal of SO after vitrectomy for PVR-associated retinal detachment [16]. Hence, the timing of SO removal is still a controversial subject [10, 15, 17, 26]. Following the removal of SO, retinal redetachment is usually attributable to the recurrence of PVR whilst the SO is still in place [16]. "Peri-silicone proliferation" or "secondary PVR" in SO-filled eyes is known to occur at the peripheral fundus [3, 22]. However, in an SO-filled eye, an examination of the peripheral fundus can be difficult, owing to the obscuring effects of light scattering, reflections or a secondary cataract. This masking effect is especially relevant for inferior parts of the retina beyond the SO bubble. Owing to the heightened risk of "peri-silicone proliferation" and of anterior retinal redetachment in SO-filled eyes, an assessment of these regions may be crucial in determining the final anatomical success of surgery [3, 22]. That anterior PVR has an impact on the development of retinal redetachment after vitreoretinal surgery is now recognized. And this awareness has led to an updating of the classification of retinal detachment with PVR being graded as type 5 [23]. Even the surgical trauma associated with SO removal can induce a recurrence of PVR, especially when this procedure is combined with extensive membrane peeling or retinectomy. After SO removal, the PVR has been reported to recur at times ranging from 0.5–34 months [24] and 0–9 months [18]. Irrespective of whether the SO is in place or has been removed, the recurrence of PVR often begins at an early stage [15, 20]. And likewise in our study, more than 80% of the retinal redetachments were observed within the first 3 months of SO removal and were due to secondary PVR [5, 16].

An early recurrence of retinal redetachment may reflect the presence of an underlying subclinical pathological state at the time of SO removal [3, 14]. Undetected or untreated PVR is not the only cause of surgical failure. In the present study, the incidence of secondary PVR was low and comparable to the frequencies documented by other studies [11, 18]. Owing to the low number of cases manifesting PVR recurrence, it was not possible to assess its impact on surgical outcome after oil removal. Another risk factor for retinal redetachment is the reopening of retinal breaks which were sealed by the surface tension of the SO bubble. Laser coagulation of critical areas prior to oil removal may be beneficial [10, 20]. The recognition that anterior PVR with tractional retinal detachment develops after vitrectomy and SO filling has resulted in a redefinition of surgical success as retinal reattachment posterior to the encircling band [3, 4, 14]. In cases of anterior PVR, an encircling band may help to relieve tractional forces and to buckle anterior retinal breaks [19]. Hence, in the present study, vitrectomy was routinely combined with the placement of an encircling band. Although this undertaking has been reported to lower the rate of retinal redetachment, retinal surgeons are not of one mind as to the benefits conferred [12, 27]. In the present study a 360° laser retinopexy was performed in cases of anterior PVR recurrence or anterior retinal redetachment, with a view to arresting a centripetal progression of this condition [1, 20, 29]. In patients with peripheral retinal detachment, this condition can be stabilized by retinal laser coagulation prior to SO removal [29]. Furthermore, prophylactic laser retinopexy may halve the incidence of retinal redetachment [20], it also appears to decrease the risk of secondary peripheral retinal tears [1] after removal of silicone oil.

The final anatomical success rates fell within the expected range [3, 15, 28]. In cases of functionally or diagnostically relevant cataracts, SO removal was combined with cataract surgery. This circumstance may explain why BCVA was not negatively associated with the time of SO retention. A similar observation has been made by other investigators [14, 28], and may be important in that it yields no evidence of SO-induced retinal toxicity [9, 25].

In contrast to patients in groups 1 and 2, those in group 3 (SO retention: > 18 months) manifested average IOPs that were at the upper limit of tolerability. Although the number of anti-glaucoma drugs administered postoperatively was highest in group 3, this circumstance was not associated with a significant decrease in IOP after SO removal. This observation indicates that the development of SO-associated refractory glaucoma is time dependent. Nevertheless, even after the retention of an SO tamponade for more than 18 months, the number of patients requiring anti-

glaucoma surgery in group 3 did not differ significantly from the frequencies in group 1 and 2.

After complex retinal detachment surgery with SO filling, the interpretation of perimetric changes is difficult, due to their usually multifactorial origin. Perimetric findings are influenced not only by IOP, but also by the extent of the retinal detachment, the presence of surgically induced scars, the status of the lens, pre-existing glaucoma, SO-induced refractive changes, the potential toxicity of several retrobulbar injections of anesthetics, and the SO itself. Hence, these changes have as yet not been documented.

Targeted handling of PVR and supplementary retinal laser treatment may account for the similar anatomical success rates between the three groups. Due to the retrospective nature of the present study, it is not possible to lay down any general guidelines as to when it may be expedient to remove the SO. However, in patients with a successfully reattached retina who then develop a PVR recurrence without SO-associated complications, the SO tamponde permits a surgeon to monitor the progression for up to 18 months without compromising the functional outcome. Thus, when the retinal situation is not unequivocally stable, a delay in SO removal could facilitate the instigation of supplementary treatment strategies, such as a 360° laser retinopexy [1, 20, 29]. In patients with recurrent PVR, the retention of SO for 12 – 18 months, and the prophylactic laser treatment of critical areas, yield anatomical and functional outcomes that are similar to those in individuals who develop no PVR and in whom the SO tamponade is removed within 4 – 12 months. SO retention for a period longer than 18 months may, even in the absence of obvious complications, lead to the development of refractory secondary glaucoma, thereby impairing the functional outcome without improving the likelihood of anatomical success.

References

1 Ambresin A, Wolfensberger TJ, Bovey EH. Management of giant retinal tears with vitrectomy, internal tamponade, and peripheral 360 degrees retinal photocoagulation. Retina 2003; 23: 622 – 628
2 Ando F. Intraocular hypertension resulting from pupillary block by silicone oil. Am J Ophthalmol 1985; 99: 87 – 88
3 Bassat IB, Desatnik H, Alalel A et al. Reduced rate of retinal detachment following silicone oil removal. Retina 2000; 20: 597 – 603
4 Blumenkranz MS, Azen SP, Aaberg DT et al. Relaxing retinotomy with silicone oil or long-acting gas in eyes with severe proliferative vitreoretinopathy. Silicone Study Report 5. Am J Ophthalmol 1993; 116: 557 – 634
5 Bodanowitz S, Hess L, Poller S et al. Management of retinal detachment following silicone-oil removal. Germ J Ophthalmol 1996; 5: 67 – 72
6 Casswell AG, Gregor ZJ. Silicone oil removal. I. The effect on the complications of silicone oil. Br Ophthalmol 1987; 71: 893 – 897
7 Casswell AG, Gregor ZJ. Silicone oil removal. II. Operative and postoperative complications. Br J Ophthalmol 1987; 71: 898 – 902
8 Chan C, Okun E. The question of ocular tolerance to intravitreal liquid silicone. A long term analysis. Ophthalmology 1986; 93: 651 – 659
9 Foerster MH, Esser J, Laqua H. Silicone oil and its influence on electrophysiologic findings. Am J Ophthalmol 1985; 99: 201 – 206
10 Franks WA, Leaver PK. Removal of silicone oil – rewards and penalties. Eye 1991; 5: 333 – 337
11 Girard P, Mimoun G, Karpouzas I et al. Clinical risk factors for proliferative vitreoretinopathy after retinal detachment surgery. Retina 1994; 14: 417 – 424
12 Heimann H, Hellmich M, Bornfeld N et al. Scleral buckling versus primary vitrectomy in rhegmatogenous retinal detachment (SPR Study): Design issues and implications. SPR Study Report No. 1. Graefe's Arch Clin Exp Ophthalmol 2001; 239: 567 – 574
13 Hoing C, Kampik A, Heidenkummer HP. Possibilities of silicone oil removal after complex vireoretinal surgery. Fortschr Ophthalmol 1991; 6: 593 – 597
14 Hutton WL, Azen SP, Blumenkranz MS et al. The effects of silicone oil removal. Silicone Study Report 6. Arch Ophthalmol 1994; 112: 778 – 785
15 Jonas JB, Budde WM, Knorr HLJ. Timing of retinal redetachment after removal of intraocular silicone oil tamponade. Am J Ophthalmol 1999; 128: 628 – 631
16 Jonas JB, Knorr HLJ, Rank RM et al. Retinal redetachment after removal of intraocular silicone oil tamponade. Br J Ophthalmol 2001; 85: 1203 – 1207
17 Kampik A, Hoing C, Heidenkummer HP. Problems and timing in the removal of silicone oil. Retina 1992; 12: 11 – 16
18 Koerner F, Boehnke M. Vitrectomy in proliferative vitreoretinopathy. Anatomical and functional results in 501 patients. Klin Monatsbl Augenkeilkd 1995; 206: 239 – 245
19 La Heil EC, Hendrikse F, Kessels AG. Results and complications of temporary silicone oil tamponade in patients with complicated retinal detachments. Retina 2001; 21: 107 – 114
20 Laidlaw H, Karia N, Bunce C et al. Is prophylactic 360° laser retinopexy protective? Risk factors for retinal redetachment after removal of silicone oil. Ophthalmology 2002; 109: 153 – 158
21 Lambrou FH, Burke JM, Aaberg TM. Effect of silicone oil on experimental traction retinal detachment. Arch Ophthalmol 1987; 105: 1269 – 1272
22 Lewis H, Burke JM, Abrams GW et al. Perisilicone proliferation after vitrectomy for proliferative vitreoretinopathy. Ophthalmology 1988; 95: 583 – 591
23 Machemer R, Aaberg TM, Freeman HM et al. An updated classification of retinal detachment with proliferative vitreoretinopathy. Am J Ophthalmol 1991; 112: 159 – 165
24 Mietz H, Heimann K. Onset and recurrence of proliferative vitreoretinopathy in various vitreoretinal diseases. Br J Ophthalmol 1995; 79: 874 – 877
25 Ober RR, Blanks JC, Ogden TE et al. Experimental retinal tolerance to liquid silicone. Retina 1983; 3: 77 – 85
26 Pavlovic S, Dick B, Schmidt KG et al. Long-term outcome after silicone oil removal. Ophthalmologe 1995; 92: 672 – 676
27 Rachal WF, Burton TC. Changing concepts of failures after retinal detachment surgery. Arch Ophthalmol 1979; 97: 480 – 483
28 Scholda Chr, Egger S, Lakits A et al. Retinal detachment after silicone oil removal. Acta Ophthalmol Scand 2000; 78: 182 – 186
29 Steel DH, Weir P, James CR. Silicone assisted argon laser confinement of recurrent proliferative vitreoretinopathy related detachment: a technique to allow silicone oil removal in problem eyes. Br J Ophthalmol 1997; 81: 765 – 778
30 The Silicone Study Group. Vitrectomy with silicone oil or perfluoropropane gas in eyes with severe proliferative vitreoretinopathy: results of a randomised clinical trial. Silicone Study Report 2. Arch Ophthalmol 1992; 110: 780 – 792
31 The Retina Society Terminology Committee . The classification of retinal detachment with proliferative vitreoretinopathy. Ophthalmology 1983; 90: 121 – 125